

Case Report

SPINDLE CELL NEOPLASM OF VAGINA CASE REPORT:

Muhammad Akram Malik^{*}, Mubshara Naz^{**}, Muhammad Sohail^{***}, Saadia Hameed^{****}

^{*}Professor of Urology, University Medical and Dental College, Faisalabad.

^{**}Associate Professor, Gynecology, University Medical and Dental College, Faisalabad.

^{***}Assistant Professor Urology, University Medical and Dental College, Faisalabad.

^{****}Professor of Pathology, University Medical and Dental College, Faisalabad.

ABSTRACT:

Vaginal spindle cell neoplasm is a very rare tumour .It consists of mesenchymal & epithelial components.

The presence of glandular structures and pattern of immunostaining, help in differentiating tumour from other vaginal neoplasm. It usually presents with slowly enlarging nodule in vagina. Reoccurrence is very rare.

KEY WORDS: Spindle cell neoplasm, mixed epithelial tumour, vaginal neoplasm.

INTRODUCTION:

Spindle cell neoplasm is a benign well circumscribed lesion, which is present in distal part of vagina in most of cases¹. They usually present in 4th or 5th decade. Common presenting complaints are painless swelling in vagina. We present a case of spindle cell neoplasm in a 42 year old female.

CASE REPORT:

Forty two year old lady presented to Gynaecology OPD Madinah Teaching Hospital, University Medical and Dental College Faisalabad with H/O painless swelling in vagina, for last 06 months. Swelling was slowly increasing in size, and there was no associated H/O any menstrual or urinary disturbance.

On examination 3×2 cm non tender cystic-firm mass on anterior vaginal wall was present protruding from introitus. It had pushed the external urethral meatus downward and laterally and it was difficult to locate the urethra, as mass had compressed the meatus. Provisional diagnosis of periurethral /Vaginal cyst was made.

The mass was excised under anesthesia. It was completely enucleated. Macroscopically it was firm and non-capsulated. Specimen was sent for histopathology, and patient was discharged on 3rd post operative day and now being followed up for any reoccurrence.

Gross findings of mass are single nodule of 3×2.5×2 cm Cut surface is grey white and homogenous. Microscopically, sections

revealed fragments of neoplastic tissue with features of spindle cell neoplasm. The neoplasm is composed of spindle shaped cell with elongated to round nuclei having immature chromatin and eosinophilic cytoplasm. Occasional mitosis is present but there is no evidence of necrosis. (Fig.. 1, 2, 3,...)

DISCUSSION:

Spindle cell neoplasm of vagina contains both epithelial and mesenchymal Components and expresses the markers for both². Mixed tumours arise in other organs like skin, salivary glands, breast and mediastinum. Spindle cell neoplasm of vagina are positive for keratin and smooth cell actin. They may be positive for CD 10 and hormone receptors but are negative for S-100 protein and glial fibrillary acid protein⁴. Spindle cell neoplasm of vagina should be differentiated from other neoplasm like leiomyoma, myofibroblastoma, dermatofibroma, solitary fibrous tumour and neurofibroma⁵.

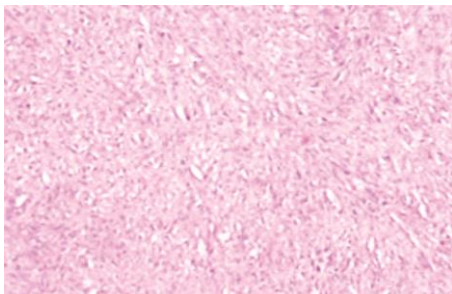
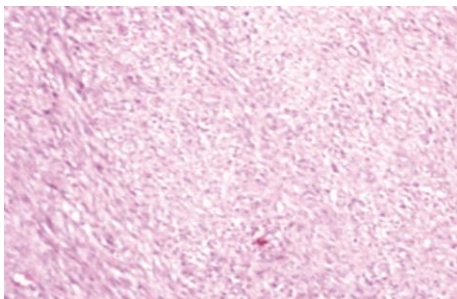
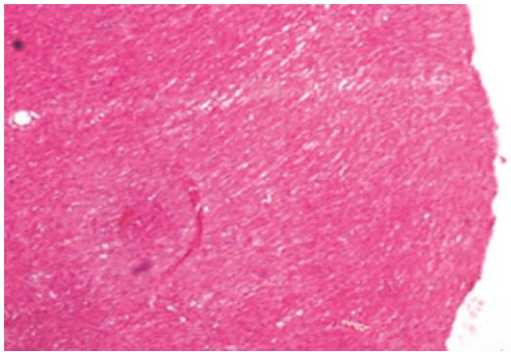
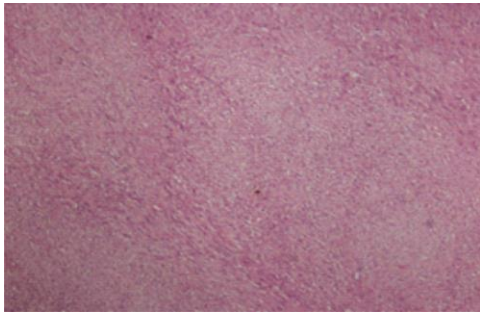
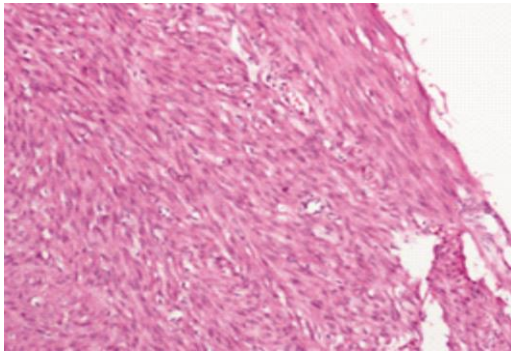
Presence of glandular structures and immunostaining help in diagnosis.

As myoepithelial cells are not present in vagina or vaginal glandular tissue it is better to call it spindle cell neoplasm rather than mixed tumours⁶.

Corresponding Author:

Muhammad Akram Malik, Professor of Urology, University of Medical & Dental College Faisalabad.

E-mail: Editor@jumdc.tuf.edu.pk



Spindle cell neoplasm is usually a benign neoplasm with uncertain histogenesis. However, tumor may recur rarely after excision and probably incomplete excision may be the cause of recurrence¹.

Very few cases of spindle cell neoplasm have been reported in the literature. Complete excision and careful follow up is the recommended treatment.

Awareness on spindle cell neoplasm helps to prevent misdiagnosis and identification of such cases

REFERENCES:

1. Branton P.A., Tavassoli F.A.: Spindle cell epithelioma, the so-called mixed tumor of the vagina. A clinicopathologic, immunohistochemical, and ultrastructural analysis of 28 cases. *Am J Surg Pathol.* 17:509-515 1993.
2. Oliva E., Gonzalez L., Dionigi A., et al.: Mixed tumors of the vagina: An immunohistochemical study of 13 cases with emphasis on cell of origin and potential aid in differential diagnosis. *Mod Pathol.* 17:1243-1250 2004.
3. Sirota R.L., Dickersin G.R., Scully R.E.: Mixed Tumors of the vagina. A clinicopathologic analysis of eight cases. *Am J Surg Pathol.* 5:413-422 1981.
4. Brustman H.: Paraganglioma of the vagina: Report of a case. *Pathol Res Pract.* 203:189-192 2007.
5. Meenakshi M., McCluggage W.G.: Myoepithelial neoplasms involving the vulva and vagina: Report of 4 cases. *Hum Pathol.* 40:1747-1753 2009.
6. Mahe E (1), Bishara M, El Demellawy D, Denardi F, Alowami S, The vaginal spindle cell epithelioma: a case report, review of the literature and discussion of potential histogenesis. *Pathol Res Pract.* 2012 Jul 15;208(7) : 424-32.

Submitted for publication: 15-10-2014

Accepted for publication: 25-10-2014