

Case Report

DOUBLE RIGHT ATRIUM OR CORTRIATRIUM DEXTRUM A RARE ENTITY:A CASE REPORT

Muhammad Furrakh Maqbool*, Khalil Iqbal*, Ahmed Noeman**

*Department of Cardiology, Punjab Institute of Cardiology, Lahore, Pakistan

**Department of Cardiac Surgery, Punjab Institute of Cardiology, Lahore, Pakistan

ABSTRACT:

Cortriatrium dextrum is an extremely rare congenital anomaly. Mostly the anomaly is diagnosed on autopsy as an isolated finding or associated with some other congenital disorder. We report a case of young female presented with palpitation and a systolic murmur.

KEY WORDS:

Cortriatrium dextrum, Triatrial heart, Double right atrium

INTRODUCTION:

Being an extremely rare congenital anomaly the reported incidence of cortriatrium is 0.1-0.4%¹. First time reported in 1868 as triatrial heart, a condition in which left or right atrium is divided into two compartments by a fibromuscular band or membrane. Embryological complete persistence of right sinus valve results in division of smooth and trabeculated parts of right atrium. The membrane that divides the atrium into two parts varies in size and shape, can have perforations or totally imperforate². In Cortriatrium dextrum the proximal chamber receives blood from both vena cavae and distal chamber is in direct contact with tricuspid valve and right atrial appendage³. Echocardiography is a useful modality for diagnosis.

Case Report:

A 23 years old female presented to Punjab institute of cardiology with history of recurrent episodic palpitations. On physical examination there was a pansystolic murmur on tricuspid area which increases with inspiration. All routine labs were normal. ECG was unremarkable except right atrial enlargement. Echocardiography showed double right atrium with a band dividing the right atrium in two

Corresponding Author:

Dr. Muhammad Furrakh Maqbool, Senior Registrar
Room No. C-22, Old Doctor Hostel, Punjab Institute
of Cardiology, jail Road, Lahore, Pakistan.
Email: justfurrakh@hotmail.com

compartments and color flow demonstrated fenestrations in fibromuscular ridge and severe tricuspid regurgitation. There was no associated congenital abnormality. Rate controlling strategy was adopted and it improved symptoms.

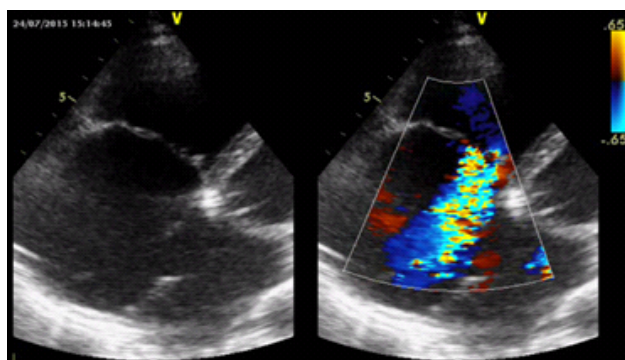


Figure 1 modified 4 chamber view showing cortriatrium dextrum and severe tr

DISCUSSION:

Cortriatrium dextrum or triatrial heart results from persistence of right sinus valve that divides the smooth and trabeculated part of right atrium. Mostly this rare congenital anomaly is found on autopsy or incidentally during imaging or as an associated finding with other congenital anomalies². This membrane or septum can present in different ways clinically depending upon size, shape, presence or absence of fenestrations. When the septation is mild condition can be asymptomatic for years, but in severe forms of this condition predominant features of right sided heart failure are observed. Symptoms suggesting elevated central venous pressure due to tricuspid valve obstruction, inferior vena cava or right ventricular outflow tract can guide towards diagnosis⁴.

Diagnosis is made most of the time on echocardiography though cardiac CT, MRI and cardiac catheterization can be used to confirm the diagnosis. Three dimensional echocardiography can also be useful if advanced modalities are not available transesophageal echocardiography with bubble study can be used to narrow the differential diagnosis⁵. Medical management for symptomatic include hemodynamic stabilization, control of ventricular rate and anticoagulation in patients with atrial fibrillation and consideration of anticoagulation prophylaxis in patients with right sided heart failure. Percutaneous technique of balloon septostomy of membrane is also an option except surgery. Surgery involves complete resection of membrane with good long term outcome⁶.

REFERENCES:

1. Hansing CE, Young WP, Rowe GG. Cor triatriatum dexter. Persistent right sinus venosus valve. *Am J Cardiol* 1972;30: 559–64.
2. Munoz Castellanos L, Kari Nivon M, Garcia Arenal F, Salinas CH. The pathological remnants of the right sinus venosus valve. A presentation of 6 hearts of the cor triatriatum dexter type [in Spanish]. *Arch Inst Cardiol Mex* 1991;61:293–301.
3. Joe BN, Poustchi-Amin M, Woodard PK. Case 56: cor triatriatum dexter. *Radiology*. 2003 Mar. 226(3):701-5.
4. Alboliras ET, Edwards WD, Driscoll DJ, Seward JB. Cor triatriatum dexter: two-dimensional echocardiographic diagnosis. *J Am Coll Cardiol* 1987;9:334–7.
5. Benyounes N, Devys JM, Cohen A. *Arch Cardiovasc Dis*. 2014 Apr;107(4):272-3.
6. Alphonso N, Norgaard MA, Newcomb A, d'Udekem Y, Brizard CP, Cochrane A. Cor triatriatum: presentation, diagnosis and long-term surgical results. *Ann Thorac Surg*. 2005 Nov. 80(5):1666-71.

{w	! ÜÇI hwb! a 9	CONTRIBUTION
1	Dr. Muhammad Furrakh Maqbool	Corresponding and main Author Senior Registrar, Punjab Institute of Cardiology, Lahore
2	Dr. Khalil Iqbal	Co-Author

Submitted for publication: 28.01.2016
Accepted for publication: 25.07.2016