

Original Article

CROSS-SECTIONAL ANALYSIS OF PAIN AND UNFAVORABLE OUTCOMES AFTER SIMPLE TOOTH EXTRACTION AT LIAQUAT UNIVERSITY HOSPITAL DENTAL OUT PATIENT DEPARTMENT

Junaid Ali, Naeem Mustafa, Muhammad Awais LUMHS
Research Forum,
Liaquat University of Medical & Health Sciences, Jamshoro

ABSTRACT:

OBJECTIVE:

To assess intensity of post-operative pain and unfavorable outcomes after simple tooth extraction.

METHODOLOGY:

This cross-sectional analysis was conducted upon a sample 130 patients selected via convenience sampling from December, 2014 to July, 2015. The selected sample of patients presented at the Liaquat University Hospital Dental Out Patient Department. Assessment of general and dental unfavorable post-operative effects experienced was done. Subsequently, telephone interviews were made during evenings for a 3 days post-op. Pain intensity was assessed on a numeric scale, and use of analgesic drugs and pain quality were recorded.

RESULTS:

The greatest possibility of appearance of an unfavorable outcomes, was on day 2 post-extraction i.e. 66.9%, followed by day 3 post-extraction (20.8%). Pain was a predominant complaint that was felt till the third day. It was highest on the day of extraction (6.33 on a numerical scale with the upper limit of ten). The intensity of pain linearly declined on day 2 to day 3 i.e. from a mean score of 3.68/10 to 1.2/10. The most notable unfavorable outcome was of swelling on both, 42.3% on day 2 and 11.5% on day 3 of post-extraction. Other outcomes included dry socket, intensified sensitivity, bleeding and temporary depressive symptoms such as general aches, loss of appetite, anxiety and negative insight.

CONCLUSION:

Patients experienced pain of varying intensity after simple uncomplicated tooth extraction maximally at the day of extraction. The unfavorable outcomes, namely swelling, bleeding and intensified sensitivity, were, however, maximally experienced on day 2 post-extraction. We recommend offering regular analgesic drugs during the first 3 days after tooth extraction to minimize the pain felt and advise greater care during the procedure to avoid unfavorable outcomes.

KEYWORDS: Tooth extraction, unfavorable outcome and post-operative pain.

INTRODUCTION:

When it comes to dental procedures, tooth extraction or having teeth "pulled" is among patients' most dreaded prospects. Also referred to as exodontia, tooth extraction involves removing a tooth from its socket in the jaw bone. There are two main types of tooth

extractions. The first being simple extractions that are performed on teeth that are visible in the mouth. They are most are usually done

Corresponding Author:

Junaid Ali

Liaquat University of Medical & Health Sciences,
Jamshoro, LUMHS Research Forum

E-mail. drjunaidalimemon@gmail.com

under a local anesthetic, with or without anti-anxiety medications or sedation. The second being surgical extractions that involve teeth that cannot easily be seen or reached in the mouth, either because they have broken off at the gum line or they have not fully erupted. Surgical extractions can be done with local anesthesia and/or conscious sedation. Patients with special medical conditions, non-cooperative patients and young children may receive general anesthesia.¹

Negative effects or symptoms and pain felt after tooth extraction are unpleasant sensory and emotional experiences unassociated with actual or potential tissue damage.² The Institute of Medicine Committee on Pain, Disability, and Chronic Illness Behavior highlighted the complex nature of pain by noting that experience of pain is more than a simple sensory process; it is a complex perception involving higher levels of the central nervous system, emotional states, and higher mental processes.³

Extraction of teeth is a common dental procedure. After tooth extraction the patient may experience pain, and there is a varying degree of severity between patients.⁴ Postoperative pain is related significantly to the amount of surgical trauma. Surgical removal of bony impactions and osseous periodontal surgery are more traumatic and produce more intense pain when compared with simple uncomplicated tooth extraction. Little information is available in the literature about pain experience after simple uncomplicated tooth extraction. Most of the literature focuses on postoperative pain after surgical removal of impacted third molars or on the effectiveness of different pharmaceutical options in combating postsurgical pain. One of the aims of this study was to assess and analyze pain experience after simple uncomplicated tooth extraction and to see if there is a need to prescribe analgesic drugs after such a procedure. The effect of patient gender, age, smoking, and educational level, the operators' status, and the extracted teeth quantity, side, and location also were investigated.⁵

Following tooth extraction, the fundic part of the bony socket fills in with connective tissue and bone, while the alveolar crest resorbs. After the wound heals and is covered with epithelium, the

edentulous ridge remains.⁶⁻¹⁵ The remains are commonly referred to as residual ridge remains. Posttooth extraction, a cascade of inflammatory reactions is immediately activated, and the extraction socket is temporarily sealed by blood clotting. Epithelial tissues begin its migration and proliferation within the first week and the disrupted tissue integrity is quickly restored. The most astonishing characteristic of extraction wound healing is that the remaining alveolar ridge bone, after extraction, experiences a constant catabolic remodeling, size of which rapidly reduces in first six months, resulting in removal of a greater part of jaw structure. Hence a lifelong therapy for edentulous is needed for the patient that cost in economic and human term makes this a major unfavorable outcome. However, the time constraints led us to investigate outcomes that appear sooner, i.e. bleeding, dry socket, heightened sensitivity and depressive symptoms.

METHODOLOGY:

This cross-sectional analysis was conducted upon a sample of 130 patients, selected via convenience sampling from December, 2014 to July, 2015. The selected sample of patients presented at the Liaquat University Hospital Dental Out Patient Department. A baseline assessment of general and dental unfavorable post-operative outcomes experienced was done. Subsequently, telephone interview of every patient for follow up, was made during evenings for a 3 days post-op. Pain intensity was assessed on a numeric scale, and use of analgesic drugs and pain quality were recorded. Informed consent was obtained before collecting data. Data was analyzed via SPSS. V.16.0 and MS. Excel 2013.

RESULTS:

Our demographically stable yet diverse sample comprised of 56.2% females and 43.8% of males.

Sample was found to be equally distributed between lower and middle socioeconomic classes. The Age of the sample ranged from 9 years to 67 years while the age mean, median and mode were 39 years, 40 years and 40 years

respectively.

The greatest likelihood of appearance of an unfavorable outcome was on day 2 post-extraction (66.9%) followed by day 3 post-extraction (20.8%). Figure 1 represents it graphically below.

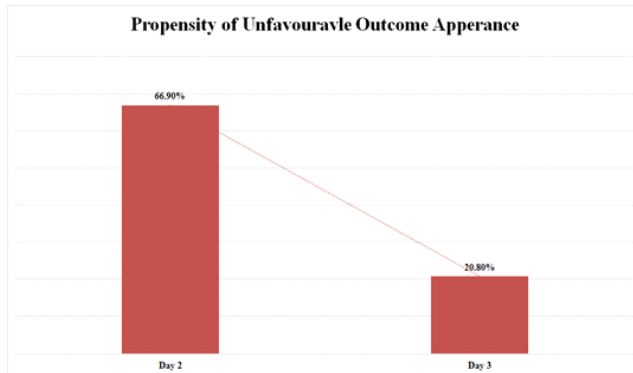


Figure 1: On the day of extraction, the patient's senses are often numbed due to the medicine and psychological effect of the procedure. The pain is also well anticipated. But the 2nd and 3rd day post-extraction, the patient wishes to recover and any unfavorable sensation or symptom is regarded with great concern. This is probably why the greatest number of unfavorable outcomes are reported on the 2nd day post-extraction. The third day, patients gets accustomed to the outcomes (e.g. heightened sensitivity) and also the healing process sets in o minimize the severity of the outcomes (e.g. bleeding).

Pain was a predominant complaint that was felt till the third day. It was highest on the day of extraction (6.33 on a numerical scale with the upper limit of ten, assessed by visual numerical scale of pain). The pain linearly subsided on day 2 (3.68) and day 3 (1.2). Figure 2 demonstrates the trend below.

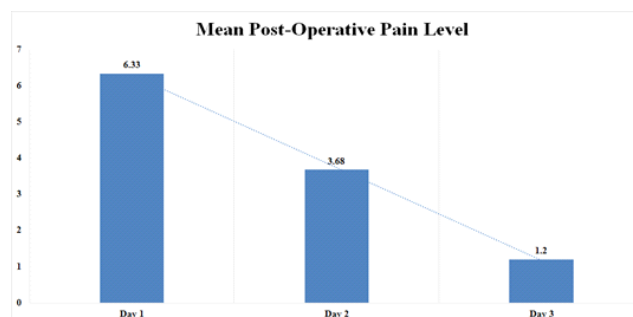


Figure 2: The patient interviews regarding self-reported numerical pain levels indicated that pain subsided from a heightened level (despite medication) to a tolerable level from day 1 to day 3 post-extraction. The subsiding yet present, levels of pain post-extraction indicate inadequacy or failure of pain relieving medication.

The most notable unfavorable outcome was swelling on both, day 2 (42.3%) and day 3 (11.5%) post-extraction. Other outcomes included dry socket, heightened sensitivity, bleeding and temporary depressive symptoms.

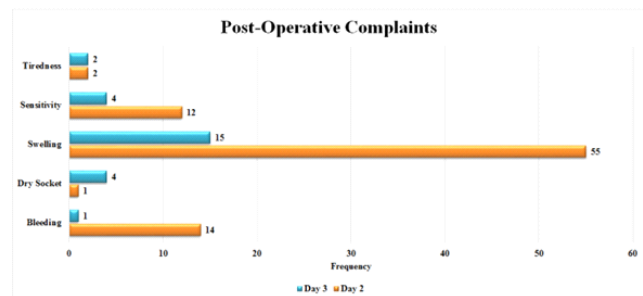


Figure 3: The graphs exemplifies a comparison of post-op complications experienced by subjects on day 2 and day 3. The most common was swelling (70 incidents), followed by intensified sensitivity (16 incidents) and bleeding (15 incidents). Most complaints decreased as the time progressed but the complaint of a dry socket was a striking contradiction. Greater incidents were reported on day 3 post-extraction than day 2 post-extraction. Levels of tiredness experienced remained same on both days.

The depressive symptoms often ignore by doctors and individuals were markedly reported by patients' post-extraction. The figure 4 below shows them clearly.

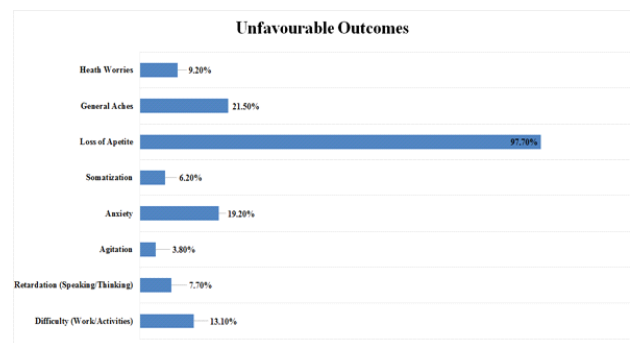


Figure 4 : the temporary symptoms of psychological distress bring about decrease in patient quality of life and need to be taken seriously. Proper counselling can prevent these symptoms from occurring. Effective pain treatment may also help significantly.

DISCUSSION:

It is surprising that despite being one of the most common oral surgical procedures, the literature gives very little attention to pain after simple tooth extraction. Indeed, most previous studies focus on either postoperative pain after surgical removal of impacted third molars, or on the effectiveness of different pharmaceutical agents in combating postoperative sequelae. To the best of our knowledge, this is the first study that presents a detailed analysis of pain experience after simple, uncomplicated tooth extraction coupled with other unfavorable post-extraction outcomes.

Our results showed that all of patients experienced moderate pain (with an average mean pain intensity score of 3.74/10) post-extraction. Among the previous studies that superficially allude to pain after simple tooth extraction, Cheung et al¹⁶ found that healing of regular simple extraction alveolus caused moderate to severe pain. Adeyemo et al¹⁷ found that simple extraction socket healing was associated with mild or moderate pain up to the third day after extraction in 9.6% of cases whereas 2.4% of patients had mild pain throughout the seventh post extraction day. Garcia et al¹⁸ pointed out that pain after simple tooth extraction is of less severity as compared with the complicated extraction that involves removal of alveolar bone and tooth sectioning. They also found that irrespective of the type of extraction, pain declined between days 1 and 5 post-surgery. The moderate intensity of post-extraction pain can be explained by the little amount of tissue damage that a simple extraction incurs. Previous studies¹⁹ support the opinion that postoperative pain reported by patients was significantly less when using minimal incisions, small mucoperiosteal flap reflection, or flapless surgery.

Literature suggests that the pre-extraction status of a tooth has a significant consequence on the pain intensity perceived after extraction.

The chronically swollen teeth cause the highest mean pain intensity scores. Some even suggest that post-operative pain increased 3-fold in patients undergoing surgical extraction of symptomatic third molars as compared with those with asymptomatic teeth.^{20,21} The reason for this is probably attributed to the co-lateral effect of various inflammatory mediators (produced by the pre-existing inflammatory condition) that produces a long-lasting increase in the activity of nociceptors.²²

Furthermore, it has been shown that the fact, in dental pulpal tissue, of substance P, vasoactive intestinal peptides, and neuropeptide Y are all increased significantly with caries-induced pulpal inflammation.²³⁻²⁶ Therefore, inflamed teeth, where the pain receptors are already sensitized due to former inflammation, and carious teeth with excited nerve endings will produce more pain when extracted as compared with non-inflamed ones where pain receptors are not sensitized.

The number of teeth extracted was found in this study to have no significant effect on the mean pain intensity scores obtained. This is in contrast with previous studies about surgical procedures. For example, Penarrocha et al²⁷ reported that the surge in number of teeth treated with peri-apical surgery amplified postoperative pain. The reason that our results are different from those of others might be due to the fact that simple tooth extraction does not incur enough tissue damage to induce sensitization of nociceptors.

There has been little literature published on patients' perception on quality of life after removal of third molars. More information is required to inform patients better, particularly as there is evidence to suggest that patients want to know more about the effects of treatment.²⁸ There is also the risk of litigation if patients are not adequately informed about the consequences of operations.

CONCLUSION:

Patients experienced pain of varying intensity after simple uncomplicated tooth extraction maximally at the day of extraction. The unfavorable outcomes, namely swelling, bleeding and intensified sensitivity, were, however, maximally experienced on day 2 post-

extraction. We recommend offering regular analgesic drugs during the first 3 days after tooth extraction to minimize the pain felt and advise greater care during the procedure to avoid unfavorable outcomes.

REFERENCES:

1. Tooth Extraction: What is Involved with Extraction and What Does it Cost? (n.d.) Consumer guide to dentistry. Retrieved from <http://www.yourdentistryguide.com/tooth-extraction/>
2. Merskey H, Bogduk N: Classification of chronic pain (ed 2). Seattle, WA, IASP, 1994
3. Osterwels M, Kleinman A, Mechanic D: Pain and disability. Washington, DC, National Academy press, 1987
4. Adams G, Wood GD, Hackett AF: Dietary intake and the extraction of third molars: A potential problem. Dent Update 23: 31, 1996
5. de Boer MP, Raghoobar GM, Stegenga B, et al: Complications after mandibular third molar extraction. Quintessence Int 26: 779, 1995
6. Euler, H.: Die Heilung von Extraktion Wunden, Deutsche Monatsc-hr. Zahn. 41: 685, 1923.
7. Schram, W. R.: Histological Study of Repair in the Maxillary Bones Following Surgery, J. A. D. A. 16: 1987, 1929.
8. Clafin, R. S.: Healing of Disturbed and Undisturbed Extraction Wounds, J. A. D. A. 23: 945, 1936.
9. Deebach, R. F.: Healing Process Following the Removal of Teeth Where Injury Great. 1, Than That Sustained in Simple Extraction Is Involved, Northwestern Univ. 1). Res. & Grad. Quart. Bull. 35: 4: 1933.
10. Christopher, E. R.: Histological Study of Bone Healing in Relation to the Extraction of Teeth, Northwestern Univ. Bull. 45: 5, 1942.
11. Mangos, J. F.: The Healing of Extraction Wounds, New Zealand I>. J. 37: 4, 1941.
12. An&r, M. H., Johnson, P. I.,, and Salrnan, I Iistological and Histochemical Investigation of Human Alveolar Socket Healing in 7 . 1 ndisturbed Extraction Wounds, J. -4. I). A. 61: 32, 1960.
13. Baloxh, K.: Histologische Untersuchungen iiber die IHeilung von Extraktionswunden nachder chirurgischen Entfernung der fazialen alveolar Wand, Monatschr. f. Stomatol. 30: 281, 1932.
14. Meyer, Il.: Heilungsvorgange in der Alveole nach normaler Zahnextraktion (experimentelle und histologische Untersuchung), Schweiz. Monatsc,hr. Zahn. 45: 571, 1935.
15. Ooi, K.: Rational Treatment of the Extraction Wound, Internat.D. J. 8: 656, 1958.
16. Cheung LK, Chow LK, Tsang MH, et al: An evaluation of complications following dental extractions using either sterile or clean gloves. Int J Oral Maxillofac Surg 30:550, 2001.
17. Adeyemo WL, Ladeinde AL, Ogunlewe MO: Clinical evaluation of postextraction site wound healing. J Contemp Dent Pract 1;7:40, 2006.
18. Garcia Garcia A, Gude Sampedro F, Gandara Rey J, et al: Trismus and pain after removal of impacted lower third molars. J Oral Maxillofac Surg 55:1223, 1997.
19. Fortin T, Bosson JL, Isidori M, et al: Effect of flapless surgery on pain experienced in implant placement using an image-guided system. Int J Oral Maxillofac Implants 21:298, 2006.
20. DA Ruta, E Bissias, S Ogston, et al: Assessing health outcomes after extraction of third molars: the postoperative symptom severity scale. Br J Oral Maxillo-fac Surg 38:480, 2000.
21. Slade GD, Foy SP, Shugars DA, et al: The impact of third molar symptoms, pain, and swelling on oral health-related quality of life. J Oral Maxillofac Surg 62:1118, 2004.
22. Levine J: Pain and analgesia: The outlook for more rational treatment. Ann Intern Med 100:269, 1984
23. Rodd HD, Boissonade FM: Comparative immunohistochemical analysis of the peptidergic innervation of human primary and permanent tooth pulp. Arch Oral Biol 47:375, 2002
24. Awawdeh L, Lundy FT, Shaw C, et al: Quantitative analysis of substance P, neurokinin A and calcitonin gene-related peptide in pulp tissue from painful and healthy human teeth. Int Endod J 35:30, 2002.

25. Caviedes-Bucheli J, Lombana N, Azuero-Holguin MM, et al: Quantification of neuropeptides (calcitonin gene-related peptide, substance P, neurokinin A, neuropeptide Y and vasoactive intestinal polypeptide) expressed in healthy and inflamed human dental pulp. *Int Endod J* 39:394, 2006.
26. Bowles WR, Withrow JC, Lepinski AM, et al: Tissue levels of immunoreactive substance P are increased in patients with irreversible pulpitis. *J Endod* 29:265, 2003.
27. Penarrocha M, Garcia B, Marti E, et al: Pain and inflammation after periapical surgery in 60 patients. *J Oral Maxillofac Surg* 64:429, 2006.
28. Humphris GM, O' Neill P, Field EA. Knowledge of wisdom tooth removal: influence of an information leaflet and validation of a questionnaire. *Br J Oral Maxillofac Surg* 1993; 31: 355-359.

SR #	AUTHOR NAME	CONTRIBUTION
1	Junaid Ali	Conception of the work and acquisition, analysis and interpretation of data for the work. Drafting the work and critical revision for important intellectual content. Final approval of the revision to be published and accountability for all aspects of the work in ensuring that questions related to the accuracy or integrity of any part of the work are appropriately investigated and resolved.
2	Muhammad Awais	Help in designing the work and acquisition, analysis and interpretation of data for the work. Drafting the work and final approval of the version to be published and accountability for all aspects of the work in ensuring that questions related to the accuracy or integrity of any part of the work are appropriately investigated and resolved.
3	Naeem Mustafa	Help in designing the work and acquisition, analysis and interpretation of data for the work. Drafting the work and final approval of the version to be published and accountability for all aspects of the work in ensuring that questions related to the accuracy or integrity of any part of the work are appropriately investigated and resolved.

Submitted for publication: 18.02.2016
 Accepted for publication: 20.06.2016